

## Diagnosis Value of Bone Marrow Study in the Disseminated Infection by Mycobacteria: Case Report

Ana Guadalupe Mauricio Campos, Francisco De Paz Andres,  
Paola Beneit, Elvira Mora, Javier Bernabeu and Jose Juan Verdu

Department of Hematology and Hemotherapy, Section of Hematologic Diagnosis,  
University General Hospital of Alicante, Alicante, Spain

Received 2012-03-29, Revised 2012-07-03; Accepted 2012-10-02

### ABSTRACT

The bone marrow examination is useful in order to get an etiologic diagnosis of cytopenias and for the detection of opportunistic diseases in immunocompromised patients. Nevertheless, its role in the diagnosis of invasive infections caused by mycobacterium has not been clearly defined. We describe the case of a 42-year-old woman who was admitted to study anemia, diarrhea and constitutional syndrome during two months with medical history of human immunodeficiency virus-1 infection, old intravenous drug user, hepatitis C virus carrier, as well as having lymph node tuberculosis and tuberculous meningitis during six years. The hematologic assessment was requested for the peripheral blood examination, which showed severe hyporegenerative anemia, rouleaux, anisopoikilocytosis and neutrophilia. In the bone marrow biopsy imprint we observed a very hypoplastic eritroid series and many macrophages with spread granularity and cytoplasm, similar to the Gaucher's cells, which presented erythrophagocytosis and birefringence enlarge forms scattered throughout the smear, suggesting mycobacteria, with these findings, we established the diagnostic suspicion of disseminated mycobacterial disease and started the empirical treatment for *Mycobacterium avium intracellulare-tuberculosis* on the same day of the procedure, the etiology infection was later confirm by cultures. In this case, the bone marrow examination allowed to establish an early diagnostic suspicion from the hematology laboratory and to start the treatment before the microbiologic result.

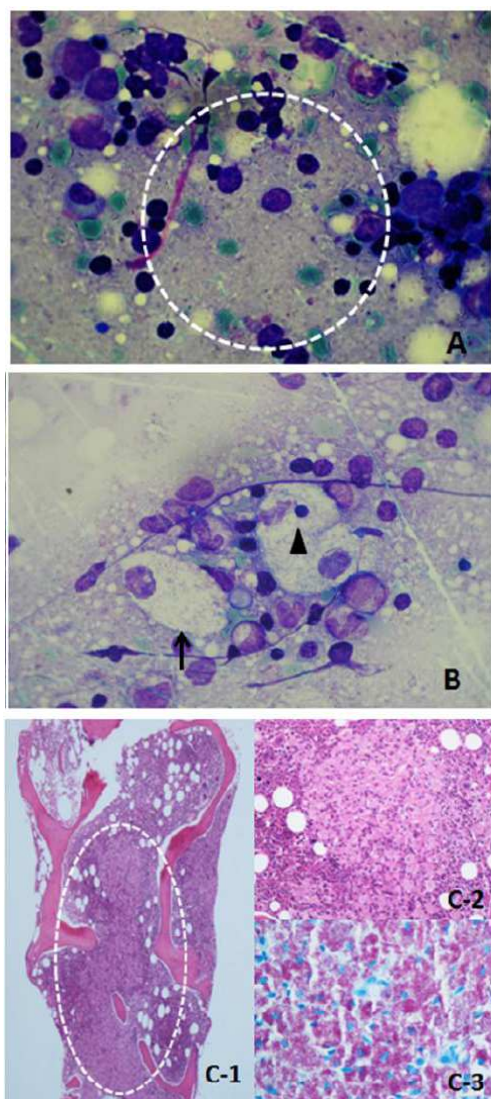
**Keywords:** Bone Marrow Biopsy, HIV Opportunistic Infections, Pseudo Gaucher's Cells, *Mycobacterium Avium Intracellulare*

### 1. INTRODUCTION

Disseminated *Mycobacterium tuberculosis* infection with involvement of liver, spleen and bone marrow is a rare complication of Human Immunodeficiency Virus (HIV) and tuberculosis co-infection and its nonspecific presentation is a challenge for diagnosis (Asl *et al.*, 2011). The *Mycobacterium avium* complex involves the most common atypical mycobacteria to cause disease in HIV/acquire immuno deficiency syndrome patients with a low T-lymphocyte CD4+ count (Cortez-Escalante *et al.*, 2012).

The Bone Marrow (BM) examination is useful in order to get an etiologic diagnosis of cytopenias and for the detection of opportunistic diseases in immunocompromised patients (Woessner and Brichs, 2006).

The role of BM study in the diagnosis of invasive infections caused by mycobacterium has not been clearly defined. Nevertheless, across the years, some studies have demonstrated that not only the diagnostic sensitivity of BM cultures was equal to that of blood cultures (Akpek *et al.*, 2001), but also the histopathological examination of BM resulted in relatively rapid identification of this kind of infections, frequently the histology and culture studies results are available after initiation of the treatment (Rose *et al.*, 2011).



**Fig. 1.** (A) Touch imprint of bone marrow biopsy. It shows many birefringent elongated forms scattered throughout the smear (inside the circle), suggesting mycobacterial infection. (B) Touch imprint of bone marrow biopsy. It demonstrates the presence of two macrophages looking like a pseudo Gaucher's cell (arrow), one of them shows erythrophagocytosis in its cytoplasm (top arrow). (C) Bone marrow biopsy. It demonstrates the infiltration by mycobacteria (C-1 and C-2), it was confirmed by the Ziehl-Neelsen stain (C-3)

We report a case in which the bone marrow study (touch imprint and biopsy) was determinant for beginning the empirical treatment for mycobacteria.

### 1.1. Case Report

#### 1.1.1. Medical History

A 42-year-old woman was admitted to study anemia, diarrhea and constitutional syndrome during 2 months. She was an old intravenous drug user with Human Immunodeficiency Virus-1 (HIV) infection during 14 years (C3 stage) with irregular adherence to the antiretroviral therapy, as well as having lymph node tuberculosis and tuberculous meningitis during 6 years and being a hepatitis C virus carrier during a year. In the initial evaluation at the emergency room was noteworthy: Fever, hypotension, severe general affectation, mucocutaneous paleness, oropharynx candidiasis, hepatosplenomegaly and high LDH and PCR levels.

#### 1.2. Laboratory Findings and Additional Tests

The hemogram showed  $4770/\text{mm}^3$  leukocytes, (88% neutrophils), hypochromic anemia ( $\text{Hb}: 82 \text{ g L}^{-1}$ ) and normal platelet count.  $\text{CD4}^+$  cells:  $5 \text{ cells } \mu\text{L}^{-1}$ . HIV viral load:  $143.472 \text{ c mL}^{-1}$ . CAT scan revealed multiple mesenteric and retroperitoneal lymphadenopathies plus hepatosplenomegaly. Colonoscopy and biopsy were done and empirical antibiotic therapy was indicated.

The hematologic assessment was requested for the peripheral blood examination because of anemia. We found severe hyporegenerative anemia, rouleaux, anisopoikilocytosis and neutrophilia with high granular density, therefore we proceeded to the bone marrow study. In the biopsy imprint we observed a very hypoplastic eritroid series, normal granulocytes, 1% blasts, 5% normal lymphocytes and many macrophages with spread granularity and cytoplasm, similar to the Gaucher's cells, which presented erythrophagocytosis and birefringent elongated forms scattered throughout the smear, suggesting infection by mycobacteria (**Fig. 1A and B**). With these findings, we established the diagnostic suspicion of disseminated mycobacteria disease and started the empirical treatment for *Mycobacterium Avium Intracellulare* (MAI)-tuberculosis on the same day of the procedure.

#### 1.3. Histopathological and Microbiological Findings

The Ziehl-Neelsen stain in bone marrow biopsy showed a lot of acid-alcohol-resistant bacilli (**Fig. 1C**). Some days later, MAI was isolated from the blood, bone marrow and colony biopsy cultures. Despite the treatment, the patient persisted with fever and altered level of consciousness, dying at the 18th day of hospital stay.

## 2. CONCLUSION

In the disseminated infection by MAI, only the BM cultures do not give an additional diagnostic value respect to the blood cultures. Successful detection of organisms in bone marrow specimens requires the use of special stains and sensitive cultures techniques. It seems that only a minority of patients are expected to have caseating granulomas on histopathological examination of bone marrow (Hakawi and Alrajhi, 2006). However, it has been studied before that the myelogram and the blood cultures together seem to have a higher value for the diagnosis of opportunistic infections (Ker *et al.*, 2002). An advantage of the bone marrow biopsy is the rapid turnaround time, with most results available within 24 hours and it is a safe and simple procedure. Patients with an uncertain diagnosis should be referred for bone marrow aspiration as soon as possible, preferably before initiation of tuberculosis treatment, although this should not delay treatment initiation if indicated (Rose *et al.*, 2011).

In this case report, the BM examination allowed to establish an early diagnostic suspicion from the hematology laboratory and to start the treatment before the microbiologic result.

## 3. REFERENCES

- Akpek, G., S.M. Lee, D.R. Gagnon, T.P. Cooley and D.G. Wright, 2001. Bone marrow aspiration, biopsy and culture in the evaluation of HIV-infected patients for invasive mycobacteria and histoplasma infections. *Am. J. Hematol.*, 67: 100-106. PMID: 11343381
- Asl, H.M., A. Alborzi and E. Sadeghi, 2011. Disseminated mycobacterium tuberculosis in an infant with AIDS. *Arch. Iran Med.*, 14: 296-298. PMID: 21726111
- Cortez-Escalante, J.J., A.M.D. Santos, G.D.C. Garnica, A.L. Sarmiento and C.N.D. Castro *et al.*, 2012. Mediastinitis and pericardial effusion in a patient with AIDS and disseminated Mycobacterium avium infection: A case report. *Rev. Soc. Bras Med. Trop.*, 45: 407-409. PMID: 22760148
- Hakawi, A.M. and A.A. Alrajhi, 2006. Tuberculosis of the bone marrow: Clinico-pathological study of 22 cases from Saudi Arabia. *Int. J. Tuberc. Lung. Dis.*, 10: 1041-1044. PMID: 16964798
- Ker, C.C., C.C. Hung, S.Y. Huang, M.Y. Chen and S.M. Hsieh *et al.*, 2002. Comparison of bone marrow studies with blood culture for etiological diagnosis of disseminated mycobacterial and fungal infection in patients with acquired immunodeficiency syndrome. *J. Microbiol. Immunol. Infect.*, 35: 89-93. PMID: 12099341
- Rose, P.C., H.S. Schaaf, B.J. Marais, R.P. Gie and D.C. Stefan, 2011. Value of bone marrow biopsy in children with suspected disseminated mycobacterial disease. *Int. J. Tuberc. Lung. Dis.*, 15: 200-204. PMID: 21219681
- Woessner, S. and L.F. Brichs, 2006. *La Citologia Optica en el Diagnostico Hematologico*. 5th Edn., Accion Medica, Madrid, ISBN-10: 8488336594, pp: 861.